



Hip Pain—It May Not Be Just From The Hip

By Charles M. Creasman, M.D.

Hip pain is a common reason for patients to see an orthopedic surgeon. The diagnosis is frequently straightforward and easily obtained through history, physical examination, and x-rays.

One of the more common causes of hip pain is arthritis. This can be secondary to wear and tear or inherited as in rheumatoid arthritis and some other connective tissue disorders. More commonly, hip pain is transient and relieved by anti-inflammatories.

Pain located over the outer aspect of the hip is frequently bursitis and sometimes tendinitis involving the muscles that attach to or cross the outer aspect of the hip joint, such as the

iliotibial band or the abductors. These also can be treated with anti-inflammatories, physical therapy, and occasionally an injection.

Some of the other times the hip bone can be affected by conditions that interrupt its blood supply leading to avascular necrosis or osteonecrosis. This can be associated with trauma, heavy drinking, and steroid use, but many times there is no known association to cause it. Pain from osteonecrosis can be intermittent, but usually will become progressive and debilitating.

Many times patients with pain in the hip have other conditions causing what we consider referred pain.

This is most commonly due to lumbar spine pathology such as a herniated disc causing sciatica.

More rare conditions, such as a labral tear or tumors, frequently require more advanced studies such as MRI or CT scan.



DR CREASMAN

FOREFOOT CAPSULITIS vs. NEUROMA

By Sanford M. Chesler, D.P.M.

A painful forefoot can indicate progression of a metabolic disease such as diabetes, rheumatoid arthritis or be an indicator of localized trauma stemming from an abnormality in gait.

As I have mentioned before when the rearfoot becomes unstable, ground reactive forces can adversely affect

the function and stability of the forefoot. These forces produce transverse plane shear and sagittal plane over-compression on both osseous and soft tissue.

Two structures potentially injured by the excessive pronated foot are the metatarsal phalangeal joint (MTPJ) capsule and the

intermetatarsal nerve. Each have distinct symptoms but also some cross-over symptoms.

MTPJ capsulitis is caused by both shear and compression. The 2nd MTPJ capsule is the most common area affected. This is due to hypermobility of the 1st ray and overload of the 2nd ray.

Inside this issue:

Cast Care: Prevention of Cast Disease	2
Wound Care: Acute wound vs. Chronic Wound	3
New Provider: Dr. C. Sabin Cranford	4

Special points of interest:

- New Glendale office is scheduled to be open in December 2007
- Enlarged Sport's Medicine Service headed by Dr. Michael Hayman and Dr. C. Sabin Cranford
- Prescott satellite office managed by Dr. Creasman
- Dr. David Van DeWynge joins AOFAS

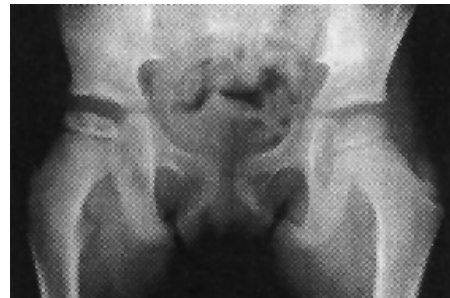HIP PAIN—IT MAY NOT BE JUST FROM THE HIP

One of the most common problems that is seen causing hip pain is a fracture. Most of these are in elderly patients secondary to a fall but can be seen even in young individuals and sometimes are related to overuse relating to stress fractures.

Children may also experience hip pain. Sometimes this is secondary to activities and growth, but could be caused by underlying abnormalities such as a childhood condition called Legg-Calvé-Perthes disease where the femoral head is affected by a lack of blood supply, usually between the ages of two and 12. Some children are born with a condition known as dysplasia where the hip socket and ball are not perfectly congruent. This may lead to early adult arthritis if not detected and treated appropriately.

Although many of the hip conditions can be treated with anti-inflammatories, a period of rest, and stretching exercises, it is important to see your physician should you have trouble walking, develop a limp lasting more than a week, if you are experiencing falling episodes, or develop rest pain. Any injury that causes pain in the groin should be evaluated with an x-ray. Certainly, if there is loss of motion such as not being able to tie your shoes or do your foot care, this would indicate potential intrinsic hip pathology. Although rare, should one develop swelling, fever, or redness, this may indicate infection and would necessitate urgent evaluation. Fortunately, most conditions are easily treated with anti-inflammatories, mild pain medicine, and physical therapy. Occasionally, however, surgery is indicated, but with ad-

vances in surgical technique and improved biomaterials, a rapid recovery and restoration of motion, and elimination of pain are common. Although traditionally, hip surgery in the past required replacing the socket with a plastic which does tend to wear slowly, newer alternative bearing surfaces are likely to extend the longevity of hip replacement.



FOREFOOT CAPSULITIS vs. NEUROMA

When the capsule is inflamed the resultant swelling affects the synovium, the flexor tendons and the adjacent intermetatarsal spaces (IM spaces).

When the IM spaces are swollen there is compression of the neurovascular bundles. This compression causes ischemic changes to the nerves and paresthesia can occur. However, physical examination of the forefoot shows majority of the pain is on the capsule and not in the IM space. Other MPJ capsules can be affected depending on the mobility of the medial or lateral foot columns. The 5th MPJ capsule is the next most common joint affected followed by the 4th MPJ.

The examination for MPJ capsulitis is dorsiflexion of the digit and direct compression of the plantar capsule and flexor tendon tissues. A positive result is a sharp non-radiating pain. Sagittal plane motion of the MPJ should be less than a 1/16 inch. Any more indicates disruption of the flexor plate and luxation of the joint [(+) Lachman Test].

An intermetatarsal neuroma is produced by direct or indirect trauma to the nerve from either internal forces similar to capsulitis and from external sources such as footwear or biomechanical injuries.

Scarring of the perineural tissue cause a thickening of the nerve and increases the potential for entrapment. An entrapped nerve causes a misfiring of the neurons with radiating, burning, and shooting pain which can travel proximally and distally.

Neuroma pain between the 3rd and 4th metatarsal heads is called a Morton's Neuroma and is the most common one. Neuroma can occur in any IM space with the 2nd IM space being the second.

Testing for an intermetatarsal neuroma is done by transverse plane compression of the forefoot with plantar thumb-pressure

between the metatarsal heads.

A (+) Tinel's sign indicates a nerve irritability. A "popping" sensation with or without radiation is a (+) Mulder's Sign. A Mulder's Sign is diagnostic for neuroma. A weight-bearing splaying of the digits is called a Sullivan's Sign. This indicates the presence of a space-occupying lesion such as a bursa or neuroma.

Treatment for capsulitis or neuroma is anti-inflammatories, physical therapy, off-loading, and biomechanical foot control.

PREVENTION OF CAST DISEASE & CAST CARE PROBLEMS

Although an old invention, casts are still the most common way of treating broken bones and several other injuries. A key to the effectiveness of a cast is good cast care. This starts from the time of application to the final cast removal.

The cast must fit the shape of the injured arm or leg correctly to provide the best possible support. While the cast is drying the arm or leg must be held in the position it was applied. The cast must be held

above heart-level for a few hours to reduce swelling and pain. Applying cold packs loosely to the casted area (too concentrated an application may cause thermal skin damage) will also help. Frequently moving the uninjured digits will prevent swelling and joint stiffness.

All casts should be kept clean and dry. Even water-proof cast material can cause skin damage. Enclose the cast in either a specialized cast protective sleeve or plastic

WOUND HEALING BY SANFORD M. CHESLER, D.P.M.

ACUTE vs. CHRONIC WOUNDS

When an injury occurs, the body's healing mechanism immediately initiates wound healing by hemocoagulation and the migration of white blood cells and platelets into the area. The purpose is to lay down collagen and remove debris from the wound. In healthy people, the acute injury progresses to healing within two weeks. However, when the patient has underlying medical issues involving the neurovascular systems, acute wounds can fail to heal in a timely fashion and become a chronic wound.

The mechanism for normal wound healing includes the migration of fibroblasts into the wound which increases the amount of collagen. Angiogenesis provides additional nutrition to regenerating tissues. When a healthy granular bed fills the wound, migration of epithelium progresses from the outer margins of the wound. The wound is considered healed after complete epithelialization and the wound reestablishes normal tensile strength.

Chronic wounds lack adequate blood supply sufficient for normal wound healing. Decreased circulation can be from internal or external sources. Constant localized pressure over a weight-bearing surface compress both venous and arterial vessels decreasing the fluid exchanges. This decreases nutrition and oxygenation of the tissues causing

tissue breakdown and death (decubitus ulceration). Other causes of acute or chronic wounds are diabetes, autoimmune diseases, chemical or radiotherapeutic agents, infections and PVD.

The dead tissue stimulates white blood cells to migrate into the area to remove this tissue. However, the decreased circulation to these areas prevent normal wound healing. The treatment of these wounds must address the internal medical and the external environment problems affecting the body part. Only when these issues are successfully addressed will wound healing occur.

The first treatment goal of acute or chronic wound care is to address these internal medical problems and the external environmental issues.

The second goal is the conversion of all chronic wounds to acute wounds by debridement of necrotic tissue, reduction of the bioburden, improvement of the wound nutrition, and changing the external environment about the wound.

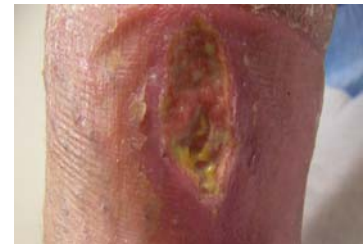Bioburden comprises non-viable tissue, excessive bacterial count, infection, edema and foreign materials. The presence of bioburden deters white blood cells from wound healing in favor of wound debridement.

The third goal is determining the proper wound dressing agents. The

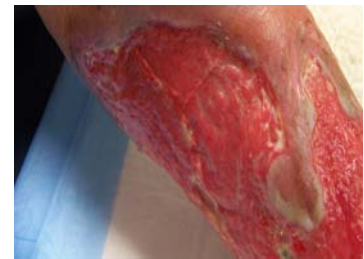
choice depends on the amount of wound drainage and amount of granulation tissue present in the wound bed.

Proper identification and conversion of chronic to acute wounds is essential for quick and uneventful wound healing.

In subsequent articles, I will discuss the different methods of wound healing including surgical debridement, wound dressings, external supportive systems and negative pressure wound treatments (Vacuum Assisted Closure).



Chronic Wound: Note the yellow fibrous tissue



Acute Wound: Note the red granulation tissues

PREVENTION OF CAST DISEASE & CAST CARE PROBLEMS

bag. If the cast does get wet, use a hair dryer under cool to remove the moisture from the cotton under-wrap. A void getting the cast wet in natural bodies of water. Waterborne parasites or contamination can enter the cast and may cause skin irritation and other problems. It is best to replace a wet cast as the cotton padding may shift and form pressure points or expose the cast material that could cause skin damage or weaken the cast support.

If the cast becomes soiled, clean it with a

damp cloth and a small amount of mild detergent. Do not expose the inside of the cast to dirt, sand or powder as this can cause skin injuries leading to infection.

Do not stuff anything into the cast as the cotton under-wrap can become displaced forming pressure points, directly injure the skin, or expose the cast material that could cause skin irritation or weaken the cast support.

Prevention of venous thrombosis is a major concern, especially in the lower

extremity. Calf pain in the casted leg that doesn't resolve with reposition or elevation of the extremity must be considered a sign of DVT and must be proved negative with venous duplex ultrasonic exam.

Preventative use of low-dosed ASA, isometric exercises, elevation of the extremities and digital movements can reduce the potential formation of a venous thrombus.

Cast care is an integral part of fracture management and must be closely monitored by physician and patient.



RETURN MAIL TO :
444 WEST OSBORN RD # 200
PHOENIX, ARIZONA 85013



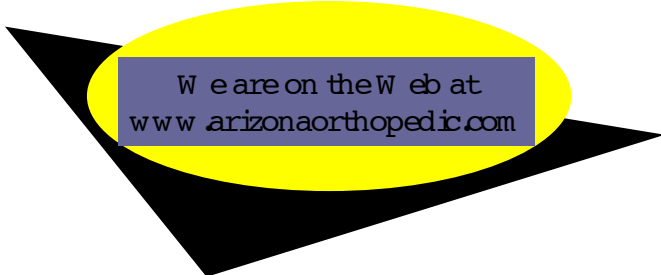
444 WEST OSBORN RD, SUITE 200
PHOENIX, ARIZONA 85013

20325 NORTH 51ST AVENUE
BLDG 4, SUITE 124
GLENDALE, ARIZONA 85308

(NE CORNER OF 51ST AVE & BEARDSLEY /101)

Phone: (602) 230-1400
Fax: (602) 230-7676

Dr Chesler's Wound Healing Clinics
Arizona Heart Hospital (602) 532-1700
Chandler Regional (480) 728-3701
Medical Center



DR. C. SABIN CRANFORD JOINS ARIZONA ORTHOPEDIC & FRACTURE SURGEONS

Dr. C. Sabin Cranford joined The Arizona Orthopedic & Fracture Surgeons in September, 2007. Dr. Cranford comes to us after completion of a one year Sports Medicine Fellowship at New England Baptist Hospital and Tufts University School of Medicine.

Dr. Cranford completed his medical training at Northwestern University Medical School. He received honors in Medicine, Obstetrics/Gynecology, Pediatrics, and Surgery clerkships. He is a member of the Alpha Omega Alpha Medical Honor Society.

He completed his general surgery internship and orthopedic residency at Northwestern University Orthopedic Surgery.

During Dr. Cranford's fellowship he was the Assistant Team Physician for the Boston Celtics, Northeastern University, Mount Ida College and Tufts University.

Dr. Cranford is an active member of the American Medical Association, American Academy of Orthopedic Surgeons,

American Orthopaedic Society for Sports Medicine, Alpha Omega Alpha Honor Society and the Arthroscopic Association of North America.

Dr. Cranford has written and published medical articles covering carpal tunnel syndromes, supracondylar humeral fractures and an anatomical study of meniscal insertions.

Dr. Cranford is married to Min-Min and they have a daughter, Georgia. Dr. Min-Min Cranford is attending a radiology fellowship at Mayo Clinic, Scottsdale.

Dr. Cranford has many sports interests including golf, weight lifting and competitive long distance running. He recently completed the Chicago marathon.

Dr. Cranford brings additional sports medicine expertise to our group as well as increased general orthopedics. He will be working in both our Phoenix and Glendale offices.



DR. C. SABIN CRANFORD